Visualization of tonsil-oral-scrubbing collection using a lighted cable and histopathological characterization of sample composition

Peng Li, Marta Mainenti, Gustavo S. Silva, Callie Schroeder, Derald J. Holtkamp, Mariáh Musskopf, Giovani Trevisan, Paul Yeske, Daniel C. L. Linhares

Abstract

Tonsil-oral-scrubbing (TOSc) can retrieve fluids from the sow's oropharyngeal and tonsillar area without snaring and shows comparable porcine reproductive and respiratory syndrome virus RNA detection rates to tonsil scrapings. This descriptive study used an endoscope-like cable with light to visualize the collection process and histopathology to characterize TOSc sample composition. Video showed that the soft palatine tonsils were reached after the TOSc collector passed the hard palate. Histopathology revealed the presence of squamous mucosal cells and small clusters of immune cells in TOSc samples. This study will help train farm staff and veterinarians on proper TOSc sample collection from sows.

Keywords: swine, tonsil-oral-scrubbing, characterization, visualization, histopathology

Received: June 27, 2024
Accepted: October 31, 2024
Published online: May 30, 2025

Resumen - Visualización de la colección de raspado oral de amígdalas utilizando un cable con luz y caracterización histopatológica de la composición de la muestra

El raspado bucal de amígdalas (TOSc por sus siglas en inglés) puede recuperar líquidos de la zona orofaríngea y amigdalar de la cerda sin tener que inmovilizarla y muestra tasas de detección de ARN del virus del síndrome reproductivo y respiratorio porcino comparables a las de los raspados de amígdalas. En este estudio descriptivo se utilizó un cable tipo endoscopio con luz para visualizar el proceso de recolección y la histopatología para caracterizar la composición de la muestra de TOSc. El video mostró que se llegó a las amígdalas palatinas blandas después de que el colector de TOSc pasó el paladar duro. La histopatología reveló la presencia de células escamosas de la mucosa y pequeños grupos de células inmunitarias en las muestras de TOSc. Este estudio ayudará a capacitar al personal de la granja y a los veterinarios en la recolección adecuada de muestras de TOSc en cerdas.

Résumé - Visualisation de la collecte par brossage oral des amygdales utilisant un câble illuminé et caractérisation histopathologique de la composition de l'échantillon

Le brossage oral des amygdales (TOSc) permet de recueillir des fluides provenant de l'oropharynx et de la région des amygdales des truies sans piégeage et montre des taux de détection de l'ARN du virus du syndrome reproducteur et respiratoire porcin comparables au grattage des amygdales. Cette étude descriptive a utilisé un câble apparenté à un endoscope avec une lumière pour visualiser le processus de collecte et l'histopathologie pour caractériser la composition des échantillons de TOSc. La vidéo a montré que les amygdales du palais mou étaient atteintes après que le collecteur TOSc ait dépassé le palais dur. L'histopathologie a montré la présence de cellules mucosales squameuses et de petits agrégats de cellules immunitaires dans les échantillons de TOSc. Cette étude aidera à former le personnel des fermes et les vétérinaires sur la méthode de collecte d'échantillon TOSc chez des truies.

PL, MM, GSS, DJH, MM, GT, DCLL: Department of Veterinary Diagnostic and Production Animal Medicine, College of Veterinary Medicine, Iowa State University, Ames, Iowa.

CS, PY: Swine Vet Center, St Peter, Minnesota.

Corresponding author: Dr Daniel C. L. Linhares, 1809 S Riverside Dr, Ames, 50011; Tel: 515-294-9358; Email: **linhares@iastate.edu**

Li P, Mainenti M, Silva G, Schroeder C, Holtkamp D, Musskopf M, Trevisan G, Yeske P, Linhares D. Visualization of tonsil-oral-scrubbing collection using a lighted cable and histopathological characterization of sample composition. *J Swine Health Prod*. 2025;33(4):147-152. **https://doi.org/10.54846/jshap/1417**

© 2025 American Association of Swine Veterinarians. This work is licensed under Creative Commons Attribution-NonCommercial 4.0 International (**https://creativecommons.org/licenses/by-nc/4.0**).

One of the complications of porcine reproductive and respiratory syndrome virus (PRRSV) control and elimination is the persistence of the virus in infected herds, which is characterized by an extended time to low prevalence status and can occasionally lead to a rebreak of PRRSV with resident isolates. Low prevalence status is defined as when the herd reaches 8 consecutive weeks of PRRSV-negative reverse transcriptase-polymerase chain reaction (RT-PCR) results in processing fluids, 3 consecutive PRRSV-negative testing using serum from due-to-wean piglets with a 30-day interval.[1-3] As sows are a major source of PRRSV transmission to neonatal piglets,[4] it is essential to assess the PRRSV infection dynamics in this subpopulation using an easy and practical sow sampling method.

Collection of blood and tonsil scraping requires the sow to be snared, which is labor-intensive and causes stress to the sow.[5,6] Oral fluids taken from individual sows are challenging to obtain under field conditions with various success rates.[7] Adapted from a sow sampling method used in the test-and-removal of African swine fever virus-infected sows in China,[8] we developed a tonsil-oral-scrubbing (TOSc) technique to rapidly retrieve biological samples from the sow's oropharyngeal and tonsillar areas without having to snare the sow. Samples taken using the TOSc method resulted in numerically higher PRRSV RNA detection rates compared to tonsil scraping and significantly higher positivity than serum samples from acutely infected sows using real-time RT-PCR.[9] The TOSc sample is thought to originate from caudal surface areas of the oral cavity including the soft palatine tonsils, allowing for detection of long-term PRRSV carrier pigs due to extended and localized virus genome replication in lymphoid tissues.[5,10] However, it is unknown if the tonsil is reached in the TOSc collection process and therefore, it is necessary to characterize the TOSc collection process and TOSc sample composition. The objective of this study was to visualize the TOSc collection process using an endoscopy-like lighted cable and to characterize the TOSc sample composition using histopathology.

Animal care and use statement

This study was conducted according to the protocol (IACUC-22-101) reviewed and approved by the Iowa State University Institutional Animal Care and Use Committee.

Materials and methods

This study used a lighted cable equipped with a camera to record the TOSc collection process in sows and a TOSc collector stained with an edible ink to visualize the targeted areas after sample collection. Furthermore, TOSc samples were examined by histopathology.

Visualization of TOSc collection process

Assembly of TOSc collector with an endoscopy-like lighted cable. The TOSc collector was constructed using a rubber thimble (Large Finger Pad, Model 098130; Staples Inc) covered by a layer of 10.2-cm × 10.2-cm cotton gauze (Model 074144; Honeywell Inc) attached to an artificial insemination rod (GoldenPig Catheter, Model 320100; IMV International) using a rubber band.

A 0.53-cm diameter, lighted, rigid cable containing a camera on the tip (Camera and Semi-rigid Cable Endoscope; TTAKMLY) was inserted in the head of the TOSc collector (Figure 1A and B). The lighted cable was fixed to the rod of the TOSc collector by a rubber band. The device was connected to a software application on a mobile phone per the manufacturer's instructions (Figure 1C).

Video recording of TOSc collection process. A 2400-sow breed-to-wean farm located in Minnesota was selected for sampling. Approximately 90 days after a PRRSV L1C.5 strain outbreak, one sow housed in a gestation stall was conveniently selected for TOSc sampling. The sow was snared while the mouth was opened with a metal speculum. The lighted cable TOSc assembly was inserted into the sow's oral cavity, passed over the hard palatine area, and moved back and forth to scrub the caudal part of the oral cavity including the soft palatine

Figure 1: Lighted cable and tonsil-oral-scrubbing (TOSc) assembly. A) Assembly of the lighted cable with TOSc collector. B) Lighted cable was buried in the head part of TOSc collector, as indicated by the arrow. C) The lighted cable-TOSc assembly was connected to a mobile phone software application. Video and still images of the target can be seen from the screen of the mobile device in real time.



tonsils. The sow was restrained during the sample collection process to reduce agitation of the lighted cable and improve focus of the video recording.

Visualization of the targeted collection areas. To assess if the TOSc collector could reach the tonsillar area, the sampling process was performed on a conveniently selected sow using a stained TOSc collector while the sow was not snared. Before collection, the sow was snared and the appearance of the sow's oral cavity was recorded using the lighted cable-TOSc assembly as previously described. Then, the head part of the TOSc collector was sprayed with an edible blue ink (Cake Craft Blue Colour Spray, 1.5 oz; Cake Craft). The ink was selected because it was easy to use, readily adhered to tissue, and safe for human consumption. The stained collector was inserted into the unrestrained sow's mouth following the same TOSc collection procedure used when the sow was snared. After TOSc collection, the sow was restrained, the mouth was held open, and the caudal portion of oral cavity was recorded using the lighted cable-TOSc assembly.

Histopathologic examination of TOSc samples

Fifteen days after live-virus inoculation of a 2500-sow breed-to-wean herd located in Iowa, TOSc samples were collected as previously described from a conveniently selected sample of 8 unrestrained sows housed in gestation stalls. The sample size was not determined through formal calculation, as this study was descriptive in nature. Instead, the number of samples was limited by budget constraints and chosen to support the exploratory objective of characterizing the composition of TOSc samples. After collection, the head of each collector was cut and placed into a 50-mL conical tube (Corning Science Mexico S.A. de C.V.) and transferred on ice to the Iowa State University Veterinary Diagnostic Laboratory for histopathological examination to characterize the composition of the TOSc sample. For each TOSc collector, a 2-cm × 3-cm piece of cotton gauze was cut with scissors and placed in a screen cassette between two biopsy sponge pads for fixation in 10% neutral buffered formalin. These were then routinely processed, embedded in paraffin wax, sectioned at 3 to 5 µm, and stained with hematoxylin and eosin for evaluation by light microscopy.

Results

Recorded TOSc collection process

The whole collection process was recorded by lighted cable-TOSc assembly (supplementary video 1; **https://doi.org/10.6084/m9.figshare.26094073**). Before reaching the caudal portion of the oral cavity, the TOSc collector had to pass the hard palatine area (Figure 2A). After passing the hard palate, the TOSc collector could easily scrub the target area, including the soft palate, the tonsils of the soft palate, and pharynx (Figure 2B). We also observed that the tongue was pressing the collector towards the dorsal surface of the caudal portion of the oral cavity, including the tonsils, when the swallow reflex was activated (Figure 2C).

Targeted collection areas with stained TOSc collector

The tonsils of the soft palate were stained with blue edible ink after TOSc collection. The tonsil crypts and tongue were densely stained. Other parts of the oral cavity, such as the hard palate and cheeks, were stained blue comparatively less (Figure 3 and supplementary videos 2 and 3 **https://doi.org/10.6084/m9.figshare.26094136**).

Histopathologic examination of TOSc samples

Under microscopic evaluation, all 8 TOSc samples mainly consisted of gauze fiber embedded with frequent squamous mucosal epithelial cells arranged in clusters and as free cells along with low to moderate numbers of rod-shaped and coccoid bacteria. In 5 of the 8 samples, squamous epithelial cells were also mixed with a few small clusters of immune cells, prevalently consisting of lymphocytes (5 of 5 samples), plasma cells (4 of 5 samples), fewer neutrophils (4 of 5 samples), eosinophils (3 of 5 samples), and rare individual round mononuclear cells with morphology suspect of macrophages (4 of 5 samples). In the remaining 3 of 8 samples, only rare individual free lymphocytes and plasma cells were observed (Figure 4).

Discussion

The caudal portion of the oral cavity, including the soft palatine tonsils, are ideal places to detect PRRSV in infected sows due to the extended and localized virus genome replication in lymphoid tissues.[5,10,12] This study used a lighted cable to visualize the TOSc collection process to confirm that the caudal oral cavity, including the soft palatine tonsils, was easily targeted after passing the hard palate. Comparison of surface appearance before and after TOSc collection with a stained collector also helped confirm that the soft palatine tonsils had been contacted.

Some limitations of this study were: 1) the collection process was visualized when the sow was restrained because the lighted cable would lose focus when agitated in the sow's mouth when the sow was not restrained; 2) it cannot be definitively differentiated whether the staining of the soft palatine tonsil was due to contact with the TOSc collector or contact with the tongue; 3) presence of macrophages could not be reliably identified within the TOSc sample by histopathology. Despite these limitations, it is reasonable to speculate from the videos that the TOSc collector targeted the soft palatine tonsil after reaching the caudal portion of oral cavity.

The presence of small clusters of immune cells, including lymphocytes, plasma cells, and rare eosinophils, mixed with squamous cells identified by histopathology also supports the idea that mucosa-associated lymphoid tissue was "scrubbed" from the tonsillar area as there is normally one thin layer of squamous epithelial cells covering tonsil crypts and fossae.[13] While low numbers of individual immune cells including lymphocytes and granulocytes are found in saliva samples,[14] the presence of clustered rather than individualized cells would suggest sample collection occurred in a location with high numbers of immune cells. Some macrophages, the primary target cell type for PRRSV infection,[15] were also observed under microscopic evaluation. Due to the thin sample size not allowing additional histologic sections for immunohistochemical analysis, additional tests confirmed that these cells were macrophages. It is plausible to infer the presence of macrophages in the lymphoid tissues considering that the macrophages are normally present within pig tonsil.[16] Mucosa-associated lymphoid tissues in the pig's oral cavity consists of paraepiglottis tonsil, lingual tonsil, and soft palatine tonsil, which is the largest.[13] Taken together, these results indicate that the TOSc reaches the soft palatine tonsillar area and supports our previous findings

Figure 2: Screenshot of tonsil-oral-scrubbing (TOSc) collection video by lighted cable-TOSc assembly. A) Image before the lighted cable-TOSc assembly passed the hard palate. B) Image after the light cable-TOSc assembly passed the hard palate. C) Image when the tongue pressed the lighted cable-TOSc assembly towards the tonsils of the soft palate after swallow reflex activation.

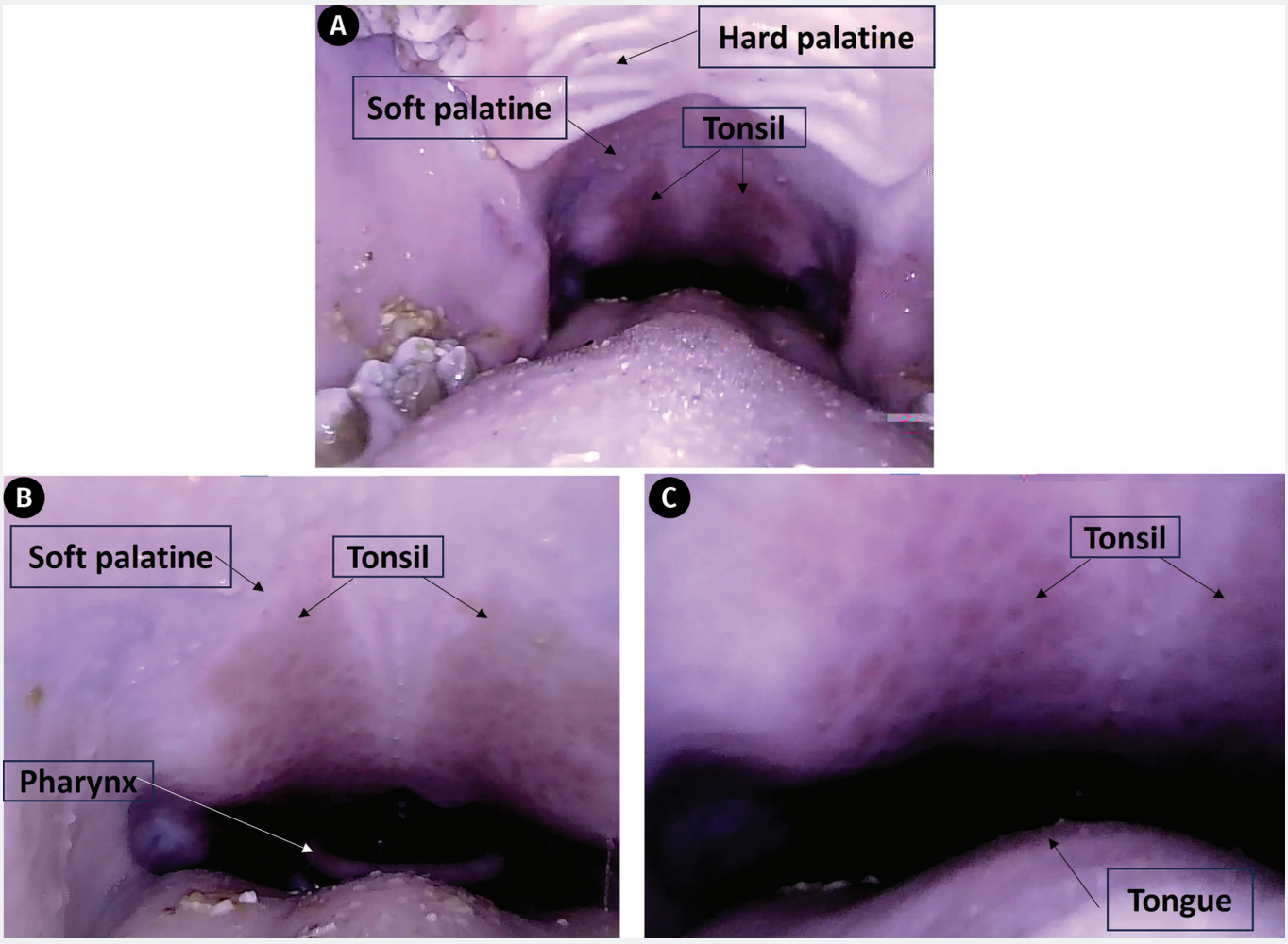

Figure 3: Comparison of the appearance of the caudal area of the oral cavity A) before and B) after collection with a stained TOSc collector. The hard palate is indicated by black arrows; soft palate is indicated by brown arrows; tonsils and tonsil crypts are indicated by red arrows; tongue is indicated by white arrows; and cheek is indicated by yellow arrows.

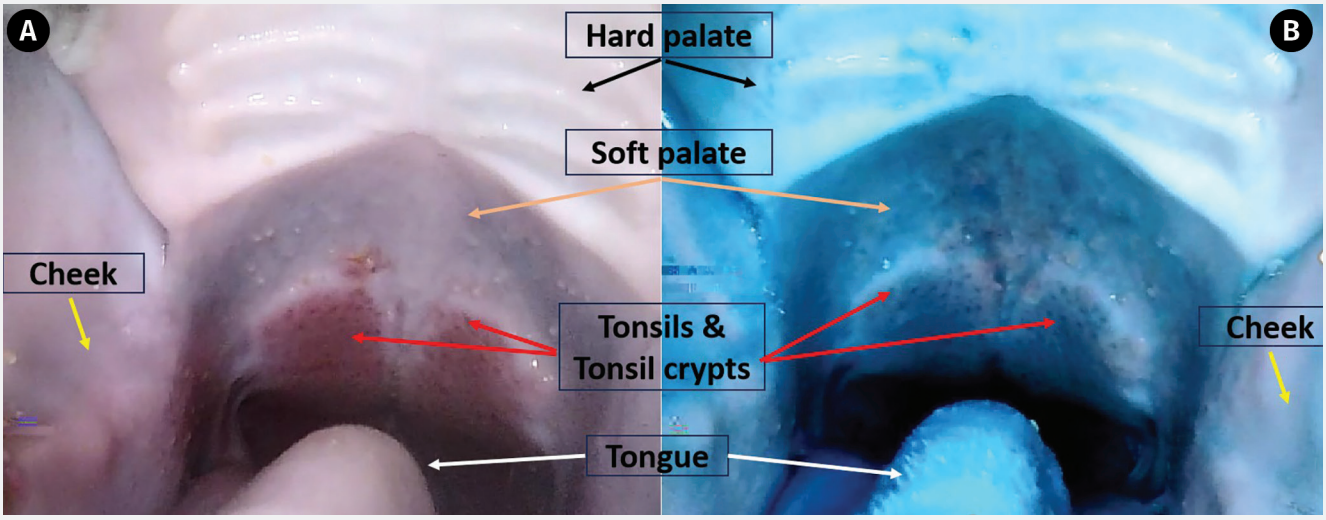

Figure 4: Histopathologic examination of tonsil-oral-scrubbing (TOSc) samples, stained with hematoxylin and eosin. A) Microscopic image of the TOSc sample composition at original magnification ×46. B) Microscopic image of the TOSc sample composition at original magnification ×300. C and D) Microscopic image of the TOSc sample composition at original magnification ×400. Clusters of cells are shown by circles. Gauze filaments are shown with asterisks. Examples of squamous epithelial cells are indicated by black arrows. Examples of lymphocytes are indicated by red squares. Eosinophils are indicated by black triangles.

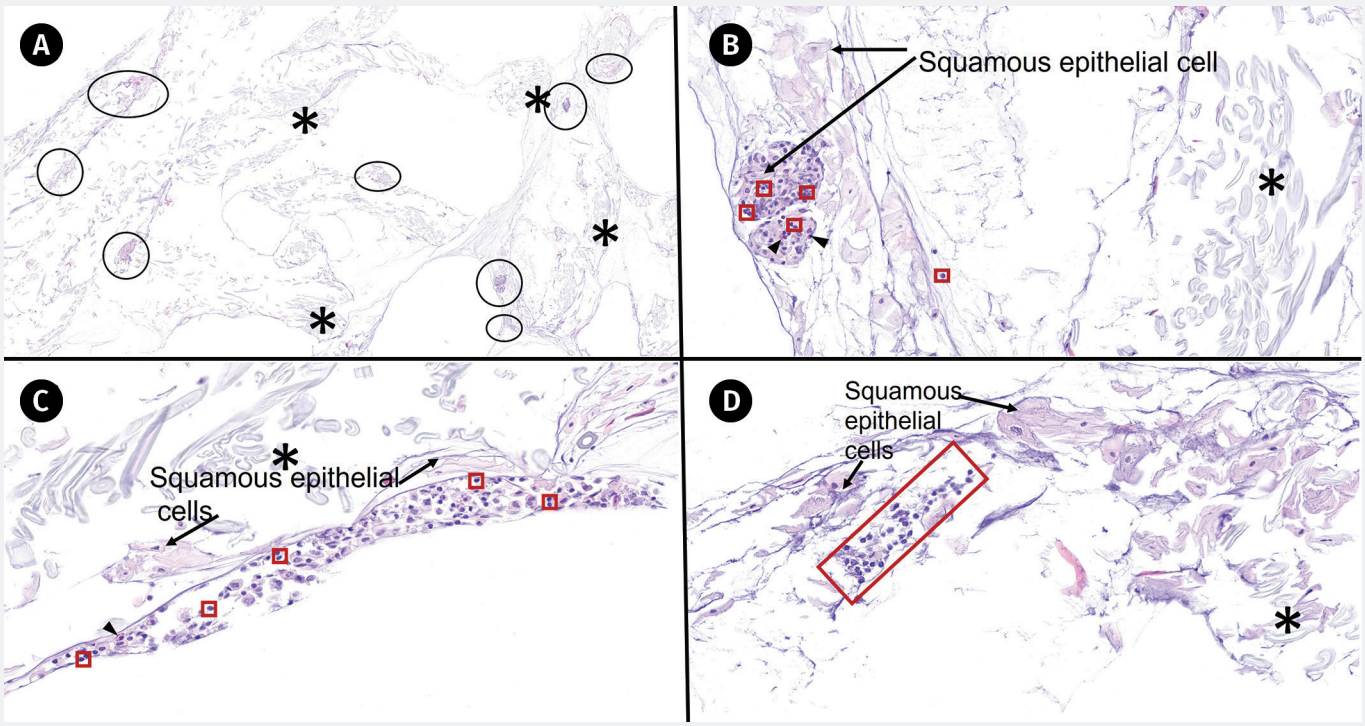

where TOSc showed comparable PRRSV RNA detection rates in PRRSV-infected sows to conventional tonsil scraping and significantly higher detection rates than serum[9] which is expected considering that PRRSV persists in lymphoid tissue longer than in serum.[5,10] Furthermore, as TOSc collection was reported to take around 20 seconds,[17] results from this study support TOSc sampling as an easy and practical individual sample type to detect PRRSV and investigate PRRSV dynamics in sow population.

This visualization process also highlighted the key points of the TOSc collection process. First, the collector had to pass the hard palate to target the soft palatine tonsils. With practice, personnel can feel that the head of the collector moves relatively freely once it reaches the caudal portion of oral cavity, which is mainly made of soft tissue. In contrast, the collector encountering hard resistance means either the sow may have bitten the collection device or the head of the device is being obstructed by the hard palate or other hard surfaces in the oral cavity. Second, the swallow reflex seems to enhance the TOSc collection process. The tongue pressed the collector towards the dorsal surface of the oral cavity, including the soft palatine tonsils (Figure 3C and supplementary video 1 **https://doi.org/10.6084/m9.figshare.26094073**), when the swallow reflex was activated. The swallow reflex increased the pressure and frequency of contact between the TOSc collector and tonsil area compared to when the sow's mouth was held open by a speculum, potentially scrubbing more fluid and cells from those caudal tissues including the tonsils. The swallow reflex was more frequently and obviously observed when the sows were not restrained.

The visualization process also explains the three major differences between TOSc and other individual oral cavity sample types: 1) all other samples, such as buccal swabs,[18] oropharyngeal swabs,[19] oropharyngeal fluid,[18] tonsil swab,[20] and tonsil scraping,[10] were collected when the sows were restrained, while TOSc can be collected without restraining the pig. 2) The TOSc is a "scrubbing" process because it takes advantage of a specific rubber thimble design[8] and stimulates the swallowing reflex allowing for longer and more rugged contact to "scrub off" lymphoid tissues from the caudal portion of oral cavity compared to a standard swabbing method.

Implications

Under the conditions of this study:

- Use of TOSc enables sampling the caudal oral cavity without snaring sows.
- Best TOSc sampling practice includes passing the collector over the hard palate.
- Visuals help train farm staff and veterinarians on proper TOSc sample collection.

Acknowledgments

Conflict of interest

None reported.

Disclaimer

Dr Linhares, a member of this journal's editorial board, was not involved in the editorial review of or decision to publish this article.

Scientific manuscripts published in the *Journal of Swine Health and Production* are peer reviewed. However, information on medications, feed, and management techniques may be specific to the research or commercial situation presented in the manuscript. It is the responsibility of the reader to use information responsibly and in accordance with the rules and regulations governing research or the practice of veterinary medicine in their country or region.

References

1. Linhares DCL, Trevisan G, Main R, Holtkamp D, Linhares L, Corzo CA. Swine disease management information program. Pork Checkoff Research Report #20-109 IPPA. Published March 4, 2023. Accessed April 25, 2025. **https://www.porkcheckoff.org/research/swine-disease-management-information-program**

2. Linhares DC, Cano JP, Torremorell M, Morrison RB. Comparison of time to PRRSV-stability and production losses between two exposure programs to control PRRSV in sow herds. *Prev Vet Med*. 2014;116(1-2):111-119. **https://doi.org/10.1016/j.prevetmed.2014.05.010**

3. Galvis JA, Corzo CA, Prada JM, Machado G. Modelling the transmission and vaccination strategy for porcine reproductive and respiratory syndrome virus. *Transbound Emerg Dis*. 2022;69(2):485-500. **https://doi.org/10.1111/tbed.14007**

4. Pileri E, Mateu E. Review on the transmission porcine reproductive and respiratory syndrome virus between pigs and farms and impact on vaccination. *Vet Res*. 2016;47(1):108. **https://doi.org/10.1186/s13567-016-0391-4**

5. Batista L, Dee SA, Rossow KD, Deen J, Pijoan C. Assessing the duration of persistence and shedding of porcine reproductive and respiratory syndrome virus in a large population of breeding-age gilts. *Can J Vet Res*. 2002;66(3):196-200.

6. Martínez-Miró S, Tecles F, Ramón M, Escribano D, Hernández F, Madrid J, Orengo J, Martínez-Subiela S, Manteca X, Cerón JJ. Causes, consequences and biomarkers of stress in swine: An update. *BMC Vet Res*. 2016;12(1):171. **https://doi.org/10.1186/s12917-016-0791-8**

7. Pol F, Dorenlor V, Eono F, Eudier S, Eveno E, Liégard-Vanhecke D, Rose N, Fablet C. Individual and pen-based oral fluid sampling: A welfare-friendly sampling method for group-housed gestating sows. *Prev Vet Med*. 2017;147:58-65. **https://doi.org/10.1016/j.prevetmed.2017.08.011**

8. Yan ZJ, Li X. Wu W, Li P. Eliminating African swine fever viruses in four large sow herds by new generation test-removal technology in China from 2018 to 2019. In: *Proceedings of the 26th International Pig Veterinary Society Congress*. IPVS; 2022:409.

9. Li P, Poeta Silva APS, Moraes DCA, Yeske P, Osemeke OH, Magalhães ES, De Sousa E Silva G, Linhares DCL. Comparison of a novel rapid sampling method to serum and tonsil scraping to detect PRRSV in acutely infected sows. *Prev Vet Med*. 2024;223:06082. **https://doi.org/10.1016/j.prevetmed.2023.106082**

10. Wills RW, Doster AR, Galeota JA, Sur J-H, Osorio FA. Duration of infection and proportion of pigs persistently infected with porcine reproductive and respiratory syndrome virus. *J Clin Microbiol*. 2003;41(1):58-62. **https://doi.org/10.1128/JCM.41.1.58-62.2003**

11. Holtkamp DJ, Torremorell M, Corzo CA, Linhares DCL, Almeida MN, Yeske P, Polson DD, Becton L, Snelson H, Donovan T, Pittman J, Johnson C, Vilalta C, Silva GS, Sanhueza J. Proposed modifications to porcine reproductive and respiratory syndrome virus herd classification. *J Swine Health Prod*. 2021;29(5):261-270. **https://doi.org/10.54846/jshap/1218**

12. Munguía-Ramírez B, Armenta-Leyva B, Giménez-Lirola L, Wang C, Zimmerman J. Surveillance on swine farms using antemortem specimens. In: Maes D, Segalés J, eds. *Optimising Pig Herd Health and Production*. Burleigh Dods Science Publishing; 2022:97-138. **https://doi.org/10.19103/AS.2002.0103.04**

13. Casteleyn C, Breugelmans S, Simoens P, Van den Broeck W. The tonsils revisited: Review of the anatomical localization and histological characteristics of the tonsils of domestic and laboratory animals. *Clin Dev Immunol*. 2011;2011:472460. **https://doi.org/10.1155/2011/472460**

14. Theda C, Hwang SH, Czajko A, Loke YJ, Leong P, Craig JM. Quantitation of the cellular content of saliva and buccal swab samples. *Sci Rep*. 2018;8(1):6944. **https://doi.org/10.1038/s41598-018-25311-0**

15. Lunney JK, Fang Y, Ladinig A, Chen N, Li Y, Rowland B, Renukaradhya GJ. Porcine reproductive and respiratory syndrome virus (PRRSV): Pathogenesis and interaction with the immune system. *Annu Rev Anim Biosci*. 2016;4:129-154. **https://doi.og/10.1146/annurev-animal-022114-111025**

16. Soldevila F, Edwards JC, Graham SP, Stevens LM, Crudgington B, Crooke HR, Werling D, Steinbach F. Characterization of the myeloid cell populations' resident in the porcine palatine tonsil. *Front Immunol*. 2018;9:1800. **https://doi.org/10.3389/fimmu.2018.01800**

17. Li P, Silva APP, Tong H, Yeske P, Dalquist L, Kelly J, Finch M, Reever AV, Reicks DL, Connor JF, Gauger PC, Holtkamp DJ, Silva GS, Trevisan G, Linhares DCL. Characterizing best practices for tonsil-oral-scrubbing (TOSc) collection for PRRSV RNA detection in sows. *Porcine Health Manag*. 2024;10:37. **https://doi.org/10.1186/s40813-024-00385-7**

18. Vosloo W, Morris J, Davis A, Giles M, Wang J, Nguyen HT, Kim PV, Quach NV, Le PT, Nguyen PH, Dang H, Tran HX, Vu PP, Hung VV, Le QT, Tran TM, Mai TMT, Le, QTV, Singanallur NB. Collection of oral fluids using cotton ropes as a sampling method to detect foot-and-mouth disease virus infection in pigs. *Transbound Emerg Dis*. 2015;62(5):e71-75. **https://doi.org/10.1111/tbed.12196**

19. Nietfeld JC, Feder I, Kramer TT, Schoneweis D, Chengappa MM. Preventing *Salmonella* infection in pigs with offsite weaning. *Swine Health Prod*. 1998;6(1):27-32.

20. Tousignant SJP, Bruner L, Schwartz J, Vannucci F, Rossow S, Marthaler DG. Longitudinal study of Senecavirus a shedding in sows and piglets on a single United States farm during an outbreak of vesicular disease. *BMC Vet Res*. 2017;13(1):277. **https://doi.org/10.1186/s12917-017-1172-7**